Special Report

Description of a novel fatigue syndrome of finished feedlot cattle following transportation

Daniel U. Thomson, PhD, DVM; Guy H. Loneragan, BVSc, PhD; Jamie N. Henningson DVM, PhD; Steve Ensley, DVM, PhD; Bhupinder Bawa, BVSc, PhD

Ensuring appropriate animal welfare is a high priority for the beef industry, and poorly defined abnormalities in the mobility of cattle at abattoirs have gained considerable attention recently. During the summer of 2013, abattoirs throughout the United States reported concerns about nonambulatory or slow and difficult to move cattle and cattle that sloughed hoof walls. This report describes various cattle that developed these mobility problems soon after arrival at an abattoir. Affected cattle had various clinical signs including tachypnea with an abdominal component to breathing, lameness, and reluctance to move. Some cattle sloughed 1 or more hoof walls while in lairage pens and were euthanized. Other cattle recovered after being rested overnight. Affected cattle had serum lactate concentration and creatine kinase activity increased from reference ranges. Histologic findings included diffuse necrosis of the epidermal laminae with degenerate collagen and perivascular infiltration of neutrophils in the underlying deep dermis, and were similar for digits that had and had not sloughed the hoof wall. With the exception of the sloughed hoof walls, the clinical signs and serum biochemical abnormalities observed in affected cattle were similar to those observed in pigs with fatigued pig syndrome, and we propose that fatigued cattle syndrome be used to describe such cattle. Although anecdotal evidence generated concern that cattle fed the β-adrenergic receptor agonist zilpaterol hydrochloride were at greater risk of developing mobility problems, compared with cattle not fed zilpaterol, this condition is likely multifactorial. Strategies to prevent this condition are needed to protect the welfare of cattle. (*J Am Vet Med Assoc* 2015;247:66–72)

The protection and promotion of appropriate animal welfare at abattoirs is a high priority for society in general and the beef industry in particular. Recently, poorly defined abnormalities in the mobility of cattle at abattoirs have garnered considerable interest from the beef industry and media. During the summer of 2013, personnel at various abattoirs throughout the United States reported concerns about cattle that were nonambulatory or slow and difficult to move and cattle with sloughed hoof walls. Anecdotal evidence, although insufficient to establish a definitive causal relationship, raised sufficient concern that cattle fed the β-adrenergic receptor agonist zilpaterol hydrochloride were at greater risk of developing mobility problems at abattoirs, compared with cattle that were not fed zilpaterol, that many abattoirs stopped accepting zilpaterol-fed cattle,[1] and the manufacturer of zilpaterol voluntarily announced a suspension of the sale of the drug in the United States and Canada on August 16, 2013.[2]

Abbreviations

BSS	Bovine stress syndrome
CK	Creatine kinase
FCS	Fatigued cattle syndrome
FPS	Fatigued pig syndrome

Many of the cattle affected with mobility problems at abattoir arrival had clinical signs that were similar to those of pigs with FPS. Fatigued pig syndrome is a multifactorial condition in which affected pigs become nonambulatory without obvious injury, trauma, or disease and refuse to walk. It is associated with many factors including stressful handling, transport, and the feeding of the β-adrenergic receptor agonist ractopamine hydrochloride at doses near the upper end of the initially approved range.[3,4] Because of the clinical similarities, we hypothesize that cattle with mobility problems at abattoir arrival may have a condition similar to FPS. In the lay press, there has been considerable speculation about the role of β-adrenergic receptor agonists, particularly zilpaterol, in the development of FCS. β-Adrenergic receptor agonists are fed to pigs and cattle during the last

From the Departments of Clinical Sciences (Thomson) and Diagnostic Medicine and Pathobiology (Henningson, Bawa), College of Veterinary Medicine, Kansas State University, Manhattan, KS 66506; Department of Animal and Food Sciences, College of Agricultural Sciences and Natural Resources, Texas Tech University, Lubbock, TX 79409 (Loneragan); and Department of Veterinary Diagnostic and Production Animal Medicine, College of Veterinary Medicine, Iowa State University, Ames, IA 50011 (Ensley).
Supported by the Beef Cattle Institute at Kansas State University.
The authors disclose that their activities in the report were undertaken as part of their institutional employment. In addition, Dr. Loneragan has accepted consulting fees from Elanco Animal Health, Intervet/Schering Plough (now known as Merck Animal Health) and Zoetis; has received honoraria and paid travel expenses from Elanco Animal Health and Zoetis; and has served as a coauthor with, and graduate advisor of, Elanco Animal Health personnel.
Address correspondence to Dr. Thomson (dthomson@vet.k-state.edu).

few weeks of the feeding period to improve feed efficiency and increase carcass leanness.[5–7] It is possible, as described herein, for cattle that have reportedly not been fed β-adrenergic receptor agonists to develop FCS.

Unlike pigs with FPS, some cattle with FCS sloughed the entire hoof wall from 1 or more digits. This results in extreme discomfort and profoundly affects the welfare of affected cattle.

Figure 1—Representative photograph of an adult *Bos taurus*–type beef crossbred steer that developed FCS and sloughed the hoof wall from the medial claw of the left pelvic limb and became recumbent in the lairage pen soon after arrival at a regional US abattoir. This steer was part of a shipment of 200 cattle of similar breed and size from a commercial feedlot that were reportedly fed the β-adrenergic receptor agonist zilpaterol hydrochloride (case 1).

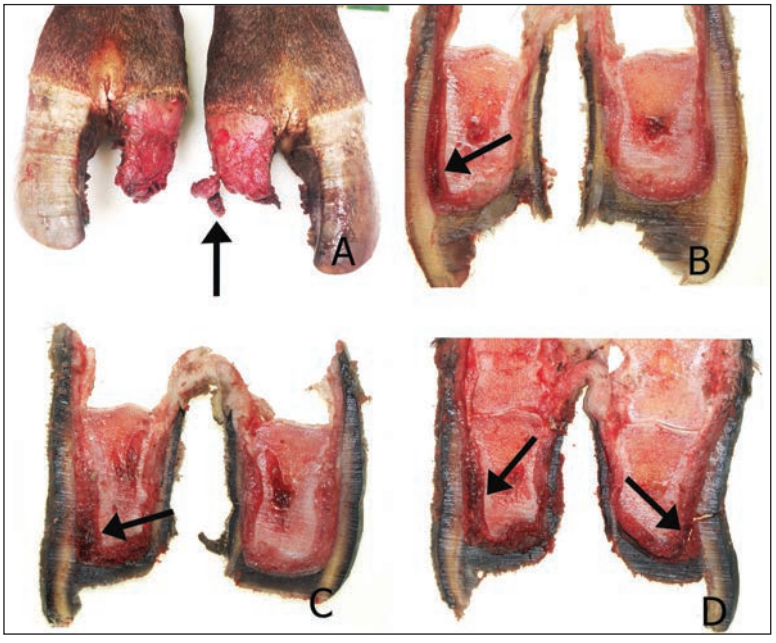

Figure 2—Representative photographs of gross lesions observed in the distal portion of intact and cross-sectioned limbs of adult *Bos taurus*–type beef crossbred cattle that developed signs of FCS soon after arrival at an abattoir. In panel A, notice the diffuse hemorrhage with necrosis and sloughing of the underlying dermal tissue (arrow) in one of the digits that had sloughed its hoof wall. In panel B, notice the mild hemorrhage in the laminae of the toe on the left (arrow), whereas the other toe appears grossly normal. In panel C, notice the hemorrhage and necrosis (arrow) in the laminae of the toe on the left, whereas the other toe remains grossly normal. In panel D, notice there is severe hemorrhage and necrosis (arrows) in the laminae of both toes in addition to some separation of the dermis from the overlying horny wall. Photographs were not all obtained from the same animal. *See* Figure 1 for remainder of key.

Therefore, it is imperative that the beef industry and affiliated veterinarians quickly learn as much as possible about FCS so that measures can be implemented to prevent the condition or at least minimize its impact on cattle welfare. Descriptive information about FCS in the scientific literature is lacking. The purpose of this report is to describe the clinical and diagnostic findings of cattle that developed clinical signs characteristic of FCS at a commercial US abattoir. These cattle were part of 2 separate shipments of cattle received by the abattoir.

Case 1

History and clinical signs—On August 5, 2013, approximately 200 *Bos taurus*–type, crossbred beef cattle < 30 months old arrived at a regional abattoir after being transported < 400 km (249 miles) from a commercial feedlot. All cattle had been fed high-concentrate finishing rations that included zilpaterol[a] in accordance with the label directions. After routine unloading, the cattle were moved without incident to lairage pens to await preslaughter inspection by federal inspectors. Each lairage pen had a concrete surface that was grooved in a blunt pyramid pattern to help prevent cattle from slipping and falling. Once in the lairage pens, many cattle became lethargic and reluctant or nonresponsive to commands to move and some became nonambulatory. While in the lairage pens, some cattle (approx 10%) sloughed the hoof wall from 1 or more of their digits (**Figure 1**). There was no apparent predilection for sloughing of the hoof wall between thoracic and pelvic limbs or between lateral and medial digits. The cattle with the sloughed hoof walls were obviously distressed and had extreme signs of pain, particularly when they attempted to bear weight on the exposed third phalanx. These signs included rapid shallow respirations, repeated lifting of the affected leg after briefly touching the affected foot to the ground, generalized muscle tremors, and refusal to stand or move.

Abattoir personnel promptly notified the appropriate on-site federal inspector, and 15 of the cattle that had sloughed hoof walls in the lairage pens were euthanized by means of penetrating captive bolt to prevent further suffering. Abattoir personnel performed necropsies on 2 of the euthanized cattle and sent tissue specimens of the distal portion of the limbs, liver, kidneys, heart, eye, and lungs and serum samples to the Kansas State Veterinary Diagnostic Laboratory. An additional 17 cattle that were reluctant or refused to move or were recumbent without evidence of injury were allowed to rest overnight in the lairage pens. Fifteen of those cattle were clinically recovered by the following morning, passed antemortem inspection, and were routinely slaughtered. The remaining 2 cattle were euthanized with a penetrating captive bolt because they did not recover sufficiently to pass antemortem inspection.

Diagnostic findings—For the 2 cattle that were necropsied, the most notable gross lesions found were the sloughed hoof walls accompanied by severe necrosis and hemorrhage in the underlying laminar dermis of the affected digits (**Figure 2**). The distal portions of limbs with and without sloughed hoof

walls were cross-sectioned so that the laminae could be evaluated grossly and histologically. In the least affected limb submitted, one of the toes had mild hemorrhage in the laminae, whereas the other toe was grossly normal. In a moderately affected limb, one toe had moderate hemorrhage and necrosis in the laminae, whereas the other toe appeared relatively normal grossly. In the most severely affected limb that had not sloughed a hoof wall, both toes had marked laminar hemorrhage and necrosis with some degree of separation from the overlying horn. When considered collectively, the gross lesions of the distal portions of the limbs of the affected cattle appeared to represent a continuum that ranged from mild laminar hemorrhage to severe laminar hemorrhage and sloughing of the hoof wall.

Histologically, the lung specimens were atelectatic and contained a few small areas where the alveolar lumina contained homogenous eosinophilic material (edema) and small amounts of extravasated erythrocytes (hemorrhage). In the liver specimens, the centrilobular and midzonal hepatocytes had pale cytoplasm with wispy eosinophilic material, and in 1 section, there was a single small aggregate of lymphocytes. Within the heart specimens, a few swollen hypereosinophilic cardiac myofibers were scattered throughout the myocardium, and the myocardium also contained protozoal organisms consistent with *Sarcocystis* spp. The distal portion of the limbs consisted of haired skin subtended by the third phalanx. For the digits that had sloughed the hoof wall, severe hemorrhage and necrosis extended from the epidermal laminae into the deep dermis. A line of fibrous connective tissue that bordered the superficial surface of the third phalanx lacked hemorrhage and necrosis. The epidermis and fibrous connective tissue were lined by a thick layer of fibrin, hemorrhage, and necrosis. The other digit on the same foot as the digit with the sloughed hoof wall, had laminae that were characterized by areas of multifocal moderate hemorrhage and necrosis. For the limbs that had not sloughed a hoof wall, the extent of laminar hemorrhage and necrosis in the digits varied and there was no evidence of inflammation. No substantial histologic lesions were identified in the kidney specimens, and no bacterial or viral pathogens were detected in any of the specimens. The mean liver selenium concentration, concentration of select serum biochemical variables, and the estimated concentration of zilpaterol in serum and retinal specimens were summarized (**Table 1**).

Case 2

History and clinical signs—On September 11, 2013, a Holstein steer < 30 months old arrived at the abattoir as part of a routine group shipment of cattle from a commercial feedlot. The cattle of this shipment were reported to not have been administered a β-adrenergic receptor agonist. In the lairage pen, the steer sloughed the hoof wall from the medial claw of both pelvic limbs and developed signs of extreme pain and distress similar to the animals in case 1. The appropriate federal inspector was notified, and the steer was euthanized by means of penetrating captive bolt and necropsied by an inspection veterinarian at the site. Tissue specimens of the distal portion of the limbs, liver, kidneys, heart, lungs, and eye and a serum sample were sent to the Kansas State Veterinary Diagnostic Laboratory. No other cattle from that shipment developed abnormal clinical signs.

Diagnostic findings—The most substantial gross abnormality identified for the steer of case 2 was loss of the hoof wall from the medial claw of both pelvic limbs. The underlying laminar and coronary dermis of the affected digits were hemorrhagic and necrotic with some portions sloughed. Histologic evaluation of the affected digits revealed diffuse necrosis and loss of the primary epidermal laminae (**Figure 3**). The underlying

Table 1—Liver selenium concentration, results for select serum biochemical variables, and estimated concentrations of zilpaterol and ractopamine in serum and retinal specimens of cattle that developed signs characteristic of FCS while in lairage pens at a regional US abattoir and were euthanized and necropsied.

Variable	Case 1	Case 2	Reference range
Liver selenium (mg/kg)	0.45	0.27	0.25–0.50
Serum lactate (mmol/L)	24.9	26.2	< 4–5
Serum glucose (mg/dL)	26	296	29–73
Serum aspartate aminotransferase (U/L)	309	226	53–156
Serum CK (U/L)	5,475	8,304	159–332
Serum zilpaterol (ppt)	80	—	NA
Serum ractopamine (ppt)	—	—	NA
Retinal zilpaterol (ppb)	45	45.8	NA
Retinal ractopamine (ppb)	—	< 10	NA

Values for case 1 represent the mean for 2 adult *Bos taurus*–type, crossbred beef cattle that were euthanized; these 2 cattle were part of a shipment of 200 cattle from a commercial feedlot that were fed zilpaterol hydrochloride in accordance with the label directions and became disabled after sloughing the hoof wall from at least 1 claw. Case 2 represents a Holstein steer < 30 months old that was part of a shipment of cattle from a feedlot that were reportedly not fed any β-adrenergic receptor agonists and became disabled after sloughing the hoof wall from the medial claw of both pelvic limbs.

NA = Not applicable. — = Not performed.

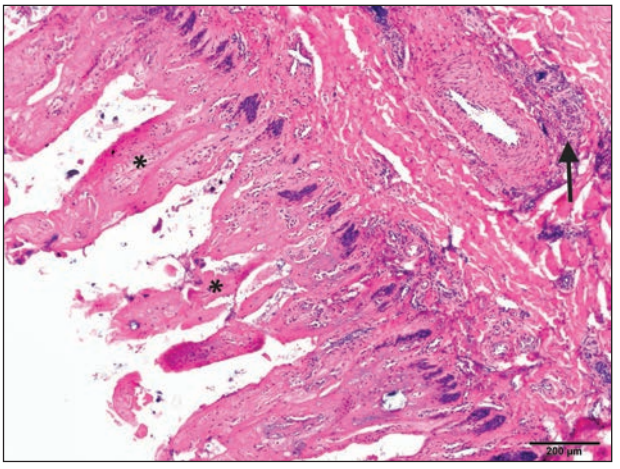

Figure 3—Photomicrograph of a section of a digit from the foot of a Holstein steer < 30 months old that was reportedly not fed any β-adrenergic receptor agonists (case 2) and developed FCS soon after arrival at an abattoir. Notice that the horny tissue of the hoof wall is absent from the section because it was sloughed prior to the steer being euthanized. There is diffuse necrosis of the epidermal laminae (asterisks), degenerate collagen in the underlying dermis, and infiltration of a moderate number of neutrophils in the perivascular region of the deep dermis (arrow). H&E stain; bar = 200 µm.

dermal laminar corium was also necrotic and contained degenerate collagen admixed with cellular and karyorrhectic debris admixed with large numbers of bacterial colonies. The deeper dermis contained moderate edema and multifocal areas of hemorrhage and was infiltrated by small to moderate numbers of neutrophils, which were most commonly observed in the perivascular areas. Blood vessels in the deeper dermis of the digit were congested and lined by hypertrophic endothelium. The lungs had multifocal areas of mild hemorrhage in the pulmonary alveolar spaces. The heart had evidence of mild subepicardial hemorrhage. The cortical interstitium of the kidney was multifocally infiltrated by small to moderate numbers of lymphocytes and plasma cells. No substantial histologic abnormalities were observed in the liver, and no bacterial or viral pathogens were identified in any of the specimens examined. The mean liver selenium concentration, concentration of select serum biochemical variables, and estimated concentrations of zilpaterol and ractopamine[b] in retinal specimens were summarized (Table 1).

Discussion

During the weeks leading up to events described in the present report, anecdotal reports of nonambulatory, slow, and difficult to move cattle and cattle sloughing hoof walls were received from various slaughter establishments. The multi-animal event described as case 1 in the present report generated widespread discussion because the owner of the slaughter establishment subsequently suspended its purchase of zilpaterol-fed cattle at all of its slaughter establishments.[1] A similar event to case 1 in terms of the number of cattle affected, the manner in which they were affected, and the inclusion of zilpaterol in their diet occurred at the same abattoir approximately a month prior to case 1. Those 2 events, as well as similar observations in other cattle that were administered zilpaterol, contributed to the decision to suspend the purchase of zilpaterol-fed cattle. Ultimately, on August 16, 2013, the drug sponsor announced that it was suspending the sale of zilpaterol in the United States and Canada.[2]

The protection and promotion of cattle welfare at abattoirs is a high priority for the beef industry. During the summer of 2013, there was a growing concern over ambulatory issues of animals arriving at various abattoirs including cattle that were difficult to move or became nonambulatory and cattle that sloughed 1 or more hoof walls soon after unloading into lairage pens. Animal welfare and behavior experts reported observations of cattle that developed signs of sore feet, had stiff gaits, were reluctant to move, and occasionally became nonambulatory with no obvious evidence of trauma or disease soon after arrival at abattoirs.[8,9] Some plant managers likewise reported concerns about cattle that were slow to move, had signs of tender or sore feet, sloughed hoof walls, and were hard to handle (some groups of cattle were lethargic, whereas others had greater-than-expected aggression when urged to move).

The first step to understanding or solving a problem is to comprehensively define that problem. The present report is one of the first to describe the history, clinical signs, and diagnostic findings of cattle with clinical signs characteristic of the mobility problems that were of growing concern for abattoirs, animal welfare and behavior experts, and feedlot managers. Although this report may not be as in-depth as some readers would like, it does provide important information about this apparently emerging condition and readers should appreciate that the data were obtained primarily from personnel at a commercial abattoir, an environment in which personnel must act expeditiously to alleviate animal suffering and maintain normal slaughter operations to the extent possible.

Histologic findings for the cattle of cases 1 and 2 revealed acute necrosis of the laminae and associated tissues in both digits with sloughed hoof walls and digits with intact hoof walls. Histologic changes in the digits of cattle with acute laminitis subsequent to carbohydrate overload include stretching of lamellae, dermal edema, hemorrhage, and abnormal basal cell morphology.[10,11] None of those histologic changes were observed in the cattle of cases 1 and 2 of this report. It is possible that the severe necrosis of the lamellar tissue of the cattle of this report obscured any histologic changes associated with carbohydrate overload; therefore, we cannot definitively rule out that those cattle did not have carbohydrate-induced laminitis. However, in our clinical experience, the degree of laminar necrosis that resulted in sloughing of the hoof walls for the cattle of this report was more severe than that observed in cattle with carbohydrate-induced laminitis. Thus, we believe that the etiology of the laminitis for the cattle in this report, which resulted in sloughed hoof walls, differs from that of carbohydrate-induced laminitis. Cattle can also slough hoof walls subsequent to selenium and ergot alkaloid toxicoses and trauma (eg, hooves getting caught in equipment or fences and then being traumatically separated from the underlying dermis). For cattle in both cases of the present report, selenium and ergot alkaloid toxicoses were considered unlikely causes of the sloughed hoof walls because liver selenium concentrations were within the reference range and laboratory analyses of feed samples from the feedlots of origin yielded negative results for ergot alkaloids. The histologic findings in the visceral organs of the cattle described in this report were considered incidental. Further research is necessary to elucidate the pathogenesis of the acute necrosis of the laminae for cattle with FCS.

The cattle described in case 1 had a multitude of clinical signs with varying severity. Most of the cattle appeared clinically normal, whereas others were mildly affected and had signs of stress and pain such as tachypnea and labored breathing, mild lameness, and a stiff gait. More severely affected cattle had extreme signs of stress and pain including tachypnea and labored breathing with an abdominal component, generalized muscle tremors, reluctance to move, severe lameness; occasionally sloughed hoof walls; and became recumbent with or without gross evidence of injury or disease. Recumbent cattle generally would not or could not stand without a substantial period of rest (ie, overnight). The affected steer described for case 2 was similar to the more severely affected cattle of case 1 in that it sloughed the hoof wall from the medial claw of both pelvic limbs. Cattle that slough the hoof wall from a

digit frequently have extreme signs of pain and require prompt action to prevent further suffering.

With the exception of the sloughed hoof walls, the spectrum of clinical signs observed for the cattle of case 1 were strikingly similar to those that have been described for pigs with FPS,[3,4] and the beef industry and lay press has adopted the term FCS to refer to this condition in cattle. Pigs with FPS frequently develop open-mouth breathing, are reluctant to move, and have a stiff gait, muscle tremors, and blotchy skin but typically do not slough their hoof walls.[3] Compared with clinically normal pigs just prior to slaughter, pigs with FPS have increased serum lactate concentration and CK activity.[4,12] The cattle evaluated in the present report had serum lactate concentrations and CK activities markedly increased from the reference ranges in addition to a reluctance to move, and the 2 cattle of case 1 also had generalized muscle tremors.

Results of a study[13] that involved finishing pigs indicate that FPS is associated with the feeding the β-adrenergic receptor agonist ractopamine, and pigs with FPS have heart rates and catecholamine concentrations increased from basal concentrations, which resulted in behavioral changes that made the pigs more difficult to handle and move at the time of shipment and less tolerant to stress. Subsequent to that study[13] and other observations, the manufacturer of ractopamine reduced the recommended dose and added a caution on the label warning that administration of ractopamine might increase the number of injured or fatigued pigs during marketing (ie, transport and lairage).[5] However, pigs not fed ractopamine can also develop FPS, and factors associated with FPS in those pigs include heavy body weight, aggressive handling, and the use of steep ramps for loading and unloading.[4]

The association between the β-adrenergic receptor agonist ractopamine and FPS and the clinical similarities between FPS and FCS have led to speculation that β-adrenergic receptor agonists, particularly zilpaterol, might be associated with the development of FCS. When administered in accordance with the label, zilpaterol has a slaughter withdrawal period of 3 days.[14] If the withdrawal of zilpaterol administration is accompanied by substantial changes to the ration or time that cattle are fed, then the simple act of no longer feeding cattle the ration that contains zilpaterol might cause diet-associated metabolic changes and represent a stressor that could contribute to the development of FCS irrespective of whether the β-adrenergic receptor agonist has a direct role in the pathogenesis of the disease.

Fatigued cattle syndrome may also have a seasonal component. Anecdotal reports from abattoir personnel indicate that FCS generally occurs during the summer months and is rarely observed in the fall, winter, or spring. This apparent correlation between FCS and warmer months could indicate that ambient temperature is a risk factor for FCS. Another potential factor might be body weight. Mean carcass weights for finished steers in the United States have increased from a range of 350 to 361 kg (771 to 795 lb) during the summer months of 2000[15] to a range of 391 to 396 kg (860 to 871 lb) during the summer months of 2012.[16] Furthermore, as the mean carcass weight increased during this period, the variation of carcass weights within shipments decreased because many feedlots began sorting cattle prior to shipment to ensure that all cattle within a shipment cohort had similar finished weights. Also, similar to FPS, the time of day when cattle are loaded into trailers for shipment, the handling techniques used to load cattle, and the distance cattle have to walk to be loaded into the trailer could be important risk factors for the development of FCS regardless of whether cattle are fed a β-adrenergic receptor agonist.[4]

The cattle assessed in the present study had serum lactate concentrations and CK activities increased from the reference ranges. Results of a study conducted by our laboratory group[c] indicate that the serum lactate concentration and CK activity did not differ significantly among zilpaterol-fed steers, ractopamine-fed steers, and steers not fed β-adrenergic receptor agonists that were maintained in a typical feedlot setting with minimal exposure to stressors. The label for zilpaterol includes a notice that cattle fed this drug may develop serum CK activity increased from basal concentrations.[7] However, the increase in the mean serum CK activity for zilpaterol-fed cattle reported in the FDA freedom of information summary for zilpaterol[14] was relatively minimal, compared with the serum CK activities measured for the cattle of the present report. An increase in serum lactate concentration indicates that fatigue and stress have depleted the muscles of glucose with a subsequent build-up of lactic acid and metabolic acidosis, which can cause muscle stiffness and tremors. Pigs with FPS that are allowed to rest will generally recover from the metabolic acidosis and be able to ambulate normally.[3] In the present report, most of the cattle of case 1 that developed mild signs of FCS and were allowed to rest overnight in the lairage pen were sufficiently recovered by the following morning to pass antemortem slaughter inspection. Although serum lactate concentration and CK activity were not measured in those cattle, we suspect they were increased from the respective reference ranges. Moreover, even though serum lactate concentration and CK activity can be increased from basal concentrations because of exercise or injury, we propose that markedly increased serum lactate concentration and CK activity combined with tachypnea, generalized muscle tremors, and a stiff gait in cattle without evidence of injury or disease are indicative of FCS. However, further characterization of FCS is warranted.

Both FCS and FPS have clinical signs that are similar to those of other conditions, which appear to be caused by a simple genetic component. For example, researchers in Australia have described BSS, which is associated with exercise-induced hyperthermia in beef cattle.[17] Cattle with BSS frequently have signs of anxiety and are hyperactive when approached by people.[17] When cattle with BSS are forced to move, they often develop skeletal muscle tremors followed by stiffness in the pelvic and thoracic limbs, and if pressured, they might become laterally recumbent with shallow breathing and an almost tetanic stiffness in their limbs.[17] Following forced movement by cattle handlers, cattle with BSS had an increased respiratory rate and increased serum lactate concentration and CK activity, compared with those for cattle without BSS.[17] A

substantial difference between the cattle with FCS described in the present report and cattle with BSS is that cattle with BSS begin to manifest clinical signs at 1 month of age, and these signs persist throughout their lives regardless of season.[17] According to anecdotal reports, FCS generally affects beef cattle that are near or at slaughter weight primarily during the summer months following a stressful event such as transport to abattoirs. In pigs, the clinical signs associated with porcine stress syndrome, or malignant hyperthermia, mimic those of BSS in cattle.[18] Although the pathogenesis of FCS and FPS might be dependent on a genetic component, that component is likely more complex than that responsible for both BSS and porcine stress syndrome, which are believed to be simple autosomal recessive disorders.[17,18]

Cattle with hereditary muscular hypertrophy (ie, double muscling) respond to stress with clinical signs similar to those described for the cattle with FCS in the present report. Results of 1 study[19] indicate that cattle with double muscling became more reluctant to move and had increased serum lactate concentration and CK activity following exposure to stress and exercise, compared with cattle without double muscling. Investigators of that study[19] described the double-muscled cattle as clumsy with stiff action of the pelvic limbs resulting from less flexion of the hip, stifle, and tibiotarsal (hock) joints and greater lumbosacral movement, compared with cattle without double muscling. When subjected to an exercise challenge that included walking approximately 8 km in < 2 hours, some double-muscled cattle died after developing clinical signs similar to those of horses with paralytic myoglobinuria, whereas other double-muscled cattle survived and had blood lactate concentrations within the reference range after 5 hours of rest.[19]

Prior to arrival at the abattoir, the cattle of case 1 had been fed zilpaterol, whereas the cattle of case 2 were reportedly not fed a β-adrenergic receptor agonist. Interestingly, zilpaterol and ractopamine were detected in the tissues from the steer of case 2 even though it was reportedly not fed either drug. The diagnostic laboratory followed the procedures published by the USDA Food Safety and Inspection Service.[20] We can only speculate on why that steer had tissue residues of β-adrenergic receptor agonists to which it was supposedly not exposed. Equipment used to mix rations that contain a β-adrenergic receptor agonist may have residues of the drug that contaminate subsequent rations that are mixed in that equipment. It is not unusual for a feedlot to have multiple rations, some that contain a β-adrenergic receptor agonist and some that do not, for cattle at various stages of the feeding period; however, the same equipment is often used to mix and deliver all the rations. So-called clean-out rations are used to remove residues of prior rations from mixing and delivery equipment (ie, these rations are mixed in and delivered by the same equipment after a ration containing a β-adrenergic receptor agonist). This ration is typically fed to various cattle within the feedyard. Theoretically, this ration could be fed to the same pens of cattle on the basis of the distance and route from the feed mill.

In the present report, zilpaterol and ractopamine residues were identified in retinal tissue. It should be noted that retinal tissue was not a tissue identified for the assay of zilpaterol or ractopamine residues when regulatory-approved maximum residue limits were established for those 2 agents. It does appear, however, that retinal tissue may be useful for evaluation of the potential exposure of cattle to β-adrenergic receptor agonists, and studies to determine depletion of ractopamine and zilpaterol are warranted.

To our knowledge, the present report is the first to describe FCS in cattle. Cattle with FCS generally manifest clinical signs of tachypnea and labored breathing, reluctance to move, and lameness, a stiff gait, or recumbency in the absence of any evidence of injury or disease and have serum lactate concentrations and CK activities markedly increased from the reference ranges. These clinical signs and diagnostic findings appear analogous to those of pigs with FPS,[3] and we believe that the 2 conditions have similar multifactorial pathogenic mechanisms. Unlike pigs with FPS, some cattle with FCS slough their hoof walls. In this report, the cattle with FCS that sloughed their hoof walls had histologic evidence of severe hemorrhage and necrosis extending from the epidermis into the deep dermis of the affected digits, which differed from the histologic lesions associated with carbohydrate-induced laminitis and suggested that the pathogenic mechanism for FCS-induced laminitis is likely different from that for carbohydrate-induced laminitis. Although the feeding of β-adrenergic receptor agonists might be a risk factor for FCS,[9] it is likely that the cause of FCS is multifactorial, and the simultaneous exposure of cattle to various, simultaneous, or stacked stressors is important for the development of FCS. Findings of this report suggested that cattle not fed a β-adrenergic receptor agonist can develop FCS in a manner analogous to FPS in pigs.[21] However, the steer of case 2 that was reportedly not fed a β-adrenergic receptor agonist and developed FCS had detectable residues of both zilpaterol and ractopamine in retinal tissue. Also, although the cattle of the present report developed FCS while in lairage pens soon after arrival at an abattoir, cattle can develop FCS anywhere, and FCS represents a welfare concern for cattle in the terminal stages of the feeding period regardless of location. More research is necessary to elucidate the metabolic, biomechanical, and pathophysiologic changes associated with FCS and investigate potential risk factors for the development of FCS such as the feeding of β-adrenergic receptor agonists, body weight, heat stress, the sorting of cattle into groups with similar body weights prior to shipment, cattle handling practices during loading and unloading, the distance cattle have to walk before loading or after unloading, the length of time cattle spend in transit, and cattle footing so that practical strategies to effectively minimize or prevent FCS can be developed and implemented.

a. Zilmax, Merck Animal Health, Summit, NJ.
b. Optaflexx, Elanco, Indianapolis, Ind.
c. Frese DA, Reinhardt CD, Bartle SJ, et al. Effect of beta-adrenergic agonists on the electrocardiogram in finishing steers (abstr) in *Proceedings*. Phi Zeta Graduate Research Competition, College of Venary Medicine, Kansas State University, 2014.

References

1. Vance A. Tyson stops buying cattle fed popular beta-agonist. *Feedstuffs*. Available at: feedstuffs.com/story-tyson-stops-buying-cattle-fed-popular-beta-agonist-45-101133. Accessed Jan 6, 2014.
2. Merck Animal Health. Merck Animal Health strengthens commitment to five steps to responsible beef. Available at: www.merck-animal-health-usa.com/news/2013-8-16.aspx. Accessed Mar 26, 2014.
3. Ritter M, Ellis M, Johnson AK, et al. The fatigued pig syndrome. *J Anim Sci Suppl* 2005;83:258.
4. Anderson DB, Ivers DJ, Benjamin ME, et al. Physiological responses of market hogs to different handling practices, in *Proceedings*. 33rd Annu Meet Amer Assoc Swine Vet 2002;399–400.
5. Elanco Animal Health. Paylean product label. Available at: www.elancocentral.com/paylean_label.pdf. Accessed Mar 27, 2014.
6. Elanco Animal Health. Optaflexx product label. Available at: www.elancocentral.com/optaflexx_label.pdf. Accessed Mar 27, 2014.
7. Merck Animal Health. Zilmax type A medicated article product label. Available at: intervetus.naccvp.com/product/view/1047465. Accessed Mar 26, 2014.
8. Edwards-Callaway L. What we know about cattle going into the packing plant from the feedlot. Beta-agonists: perceptions versus reality, in *Proceedings*. Natl Cattlemen's Beef Assoc Summer Conf 2013.
9. Grandin T. Panel Discussion 4: What needs to be done next? Recommendation–what additional studies might need to be done, Beta agonists: perceptions versus reality. Beef Technologies Forum II, in *Proceedings*. Natl Cattlemen's Beef Assoc Summer Conf 2013.
10. Greenough PR. *Bovine laminitis and lameness: a hands-on approach*. Philadelphia: Saunders Elsevier, 2007;51–52.
11. Thoefner MB, Wattle O, Pollitt CC, et al. Histopathology of oligofructose-induced acute laminitis in heifers. *J Dairy Sci* 2005;88:2774–2782.
12. Ivers DJ, Richardson LF, Jones DJ, et al. Physiological comparison of downer and non-downer pigs following transportation and unloading at a packing plant. *J Anim Sci Suppl* 2002;80:39.
13. Marchant-Forde JN, Lay DC Jr, Pajor EA, et al. The effects of ractopamine on the behaviour and physiology of finishing pigs. *J Anim Sci* 2003;81:416–422.
14. FDA. Freedom of information summary, original new animal drug application NADA 141-258, Zilmax (zilpaterol hydrochloride) type A medicated article for cattle fed in confinement for slaughter. Available at: www.fda.gov/downloads/AnimalVeterinary/Products/ApprovedAnimalDrugProducts/FOIFOIADrugSummar/ucm051412.pdf. Accessed Mar 28, 2014.
15. USDA National Agricultural Statistics Service. Livestock Slaughter 2000 Summary. Available at: usda.mannlib.cornell.edu/usda/nass/LiveSlauSu//2000s/2001/LiveSlauSu-03-02-2001.pdf. Accessed Jan 8, 2013.
16. USDA National Agricultural Statistics Service. Livestock Slaughter 2012 Summary. Available at: usda.mannlib.cornell.edu/usda/nass/LiveSlauSu//2010s/2013/LiveSlauSu-04-22-2013.pdf. Accessed Jan 8, 2013.
17. Hill BD, McManus AC, Brown NN, et al. A bovine stress syndrome associated with exercise-induced hyperthermia. *Aust Vet J* 2000;78:38–43.
18. Jackson PGG, Cockcroft PD. Diseases of the musculoskeletal system. In: *Handbook of pig medicine*. Philadelphia: Saunders Elsevier, 2007;53–54.
19. Holmes JHG, Ashmore CR, Robinson DW. Effects of stress on cattle with hereditary muscular hypertrophy. *J Anim Sci* 1973;36:684–694.
20. USDA Food Safety and Inspection Service. CLG-AGON 1.04. Screening and confirmation of beta-agonists by HPLC/MS/MS.
21. Broom DM, Johnson KG. Assessing welfare: short-term responses. In: *Stress and animal welfare*. Oxford, England: Chapman and Hall, 1993;87–110.